

511-2018-08-29-anatomy

Rick Gilmore

2018-09-03 08:32:47

Prelude



<https://www.youtube.com/snO68ajTOpM>

Today's Topics

- Wrap-up on functional methods
- Gross neuroanatomy

Neuroscience Seminar

"Combinatorial Strategies for the Plasticity and Regeneration of the Injured Spinal Cord"

Dr. Xiao-Ming Xu Indiana University


Wednesday, September 5, 2018 4:00 - 5:00 P.M.

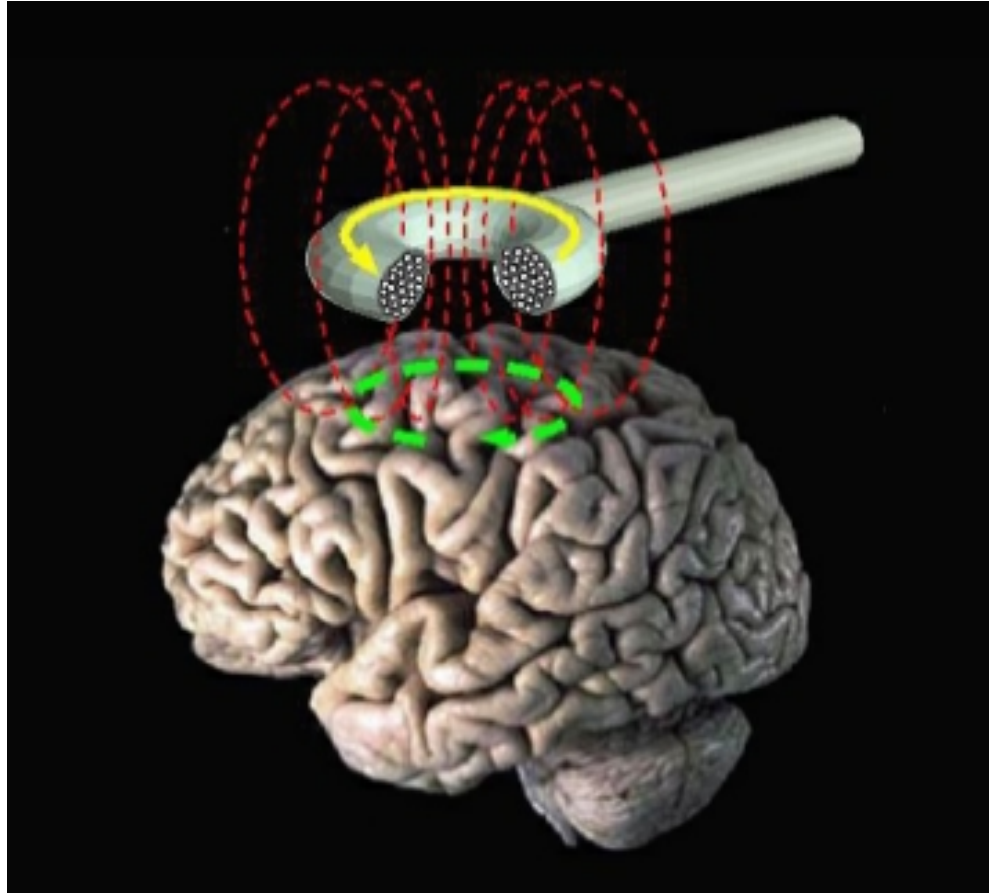
108 Wartik Lab

Wrap-up on functional methods

Stimulating the brain

- Pharmacological
- Electrical (Transcranial Direct Current Stimulation - [tDCS](#))
- Magnetic (Transcranial magnetic stimulation - [TMS](#))



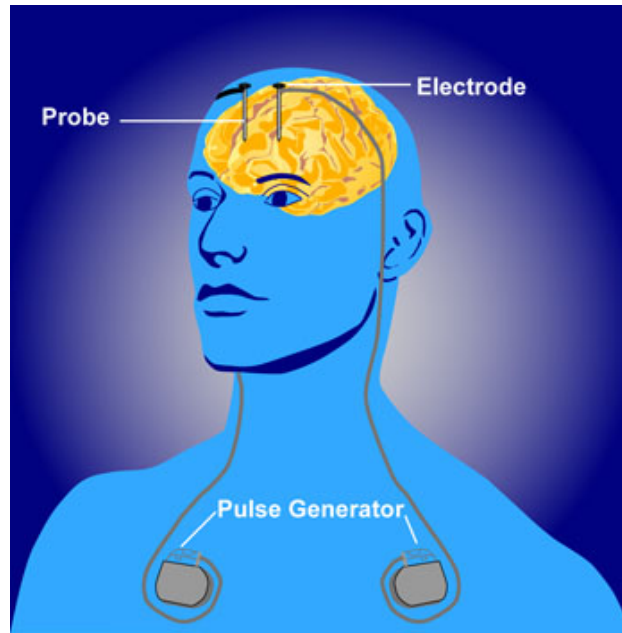


Stimulating the brain

- Spatial/temporal resolution?
- Assume stimulation mimics natural activity?

Deep brain stimulation as therapy

- Depression
- Epilepsy
- Parkinson's Disease



http://www.nimh.nih.gov/images/health-and-outreach/mental-health-topic-brain-stimulation-therapies/dbs_60715_3.jpg



<https://youtu.be/KDjWdtDyz5I>

Optogenetics



Optogenetics

- Gene splicing techniques insert light-sensitive molecules into neuronal membranes
- Application of light at specific wavelengths alters neuronal function
- Cell-type specific and temporally precise control

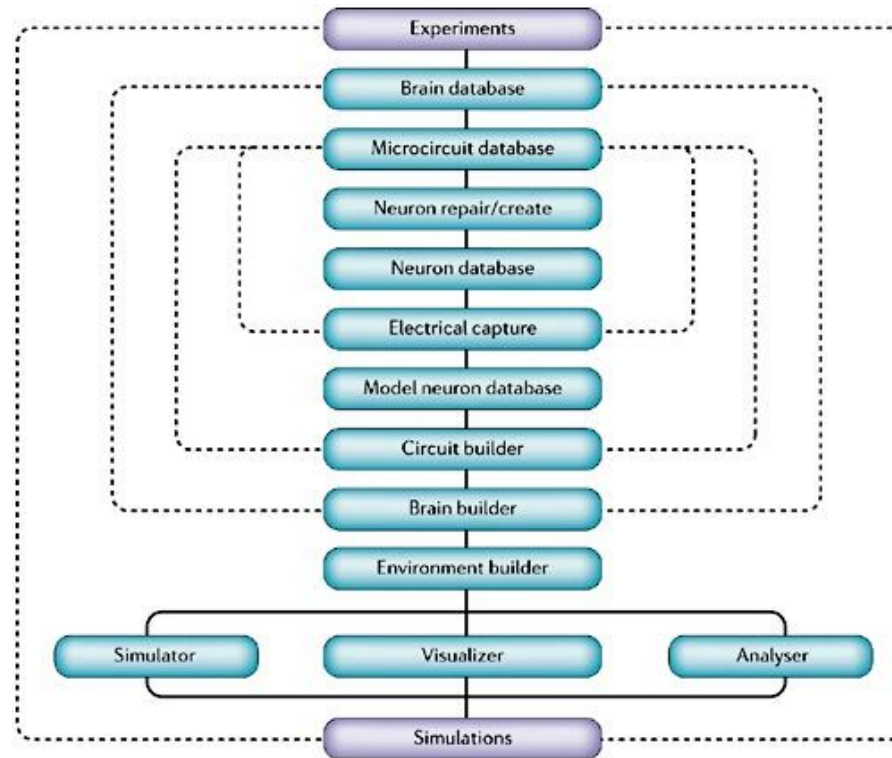


<https://youtu.be/FlGbznBmx8M>

Simulating the brain

- Computer/mathematical models of brain function
- Example: neural networks
- Cheap, noninvasive, can be stimulated or “lesioned”

Blue Brain project



Copyright © 2006 Nature Publishing Group
Nature Reviews | Neuroscience

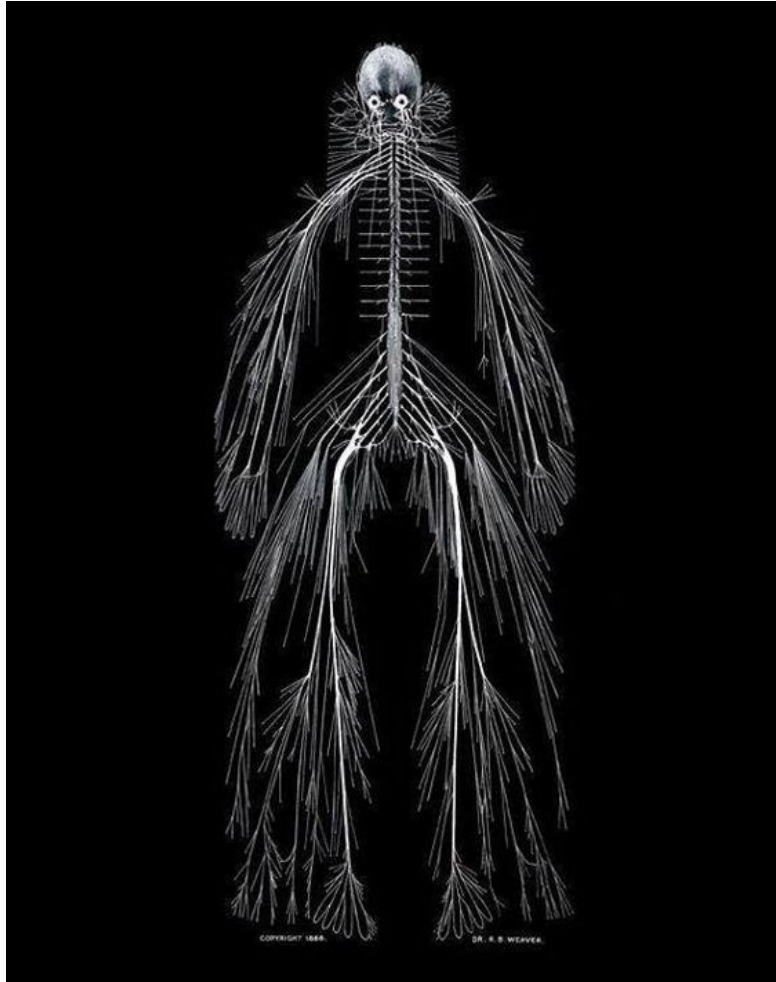
Markram, 2006



Main points

- Multiple structural, functional methods
- Different levels of spatial & temporal analysis
- Functional tools have different strengths & weaknesses

Gross neuroanatomy



<https://www.pastmedicalhistory.co.uk/the-nervous-system-of-harriet-cole/>

Brain anatomy through dance

Finding our way around

Anterior/Posterior

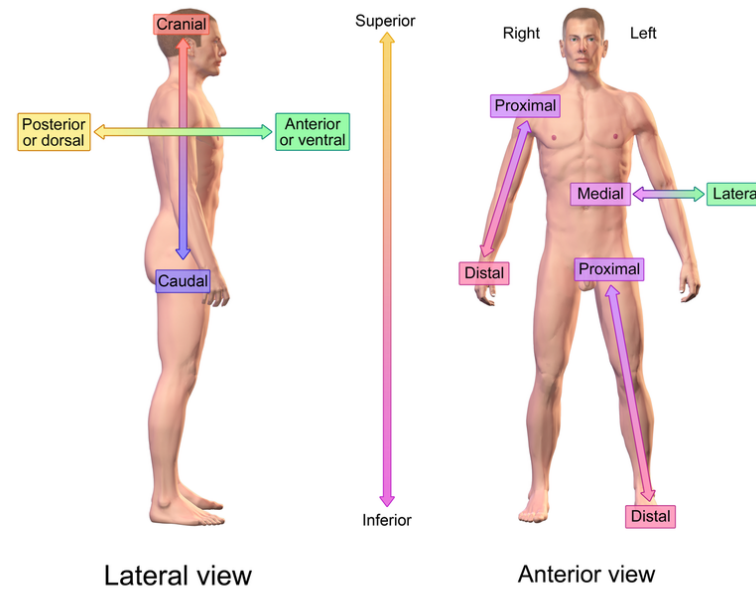
Medial/Lateral

Superior/Inferior

Dorsal/Ventral

Rostral/Caudal

Directional image

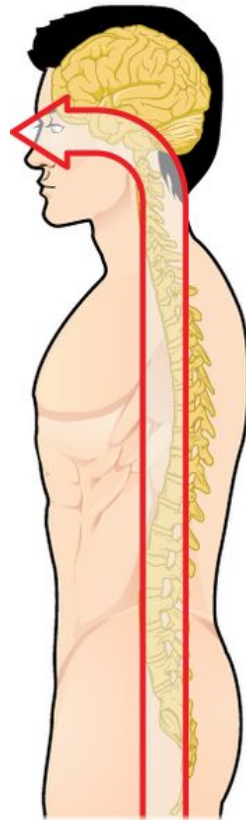


Directional References

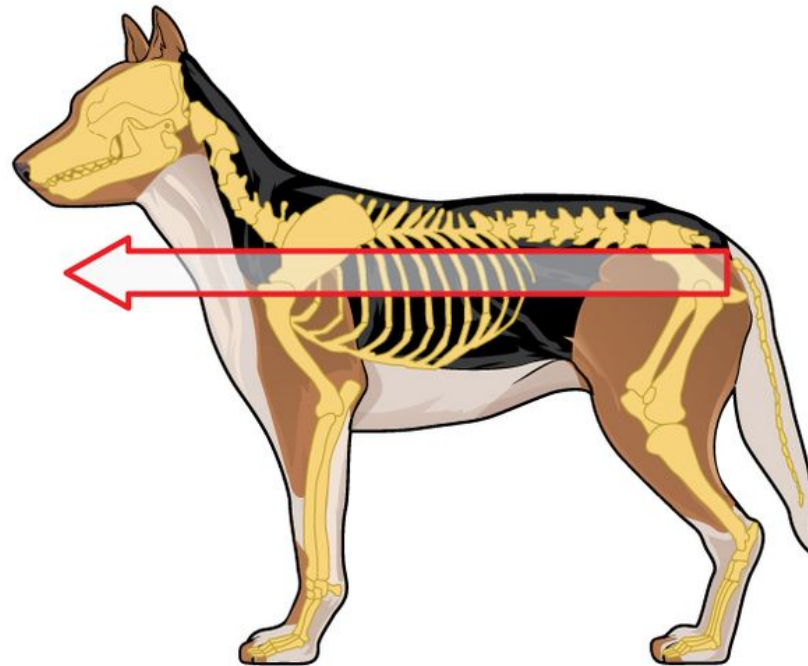
https://upload.wikimedia.org/wikipedia/commons/thumb/e/e7/Blausen_0019_AnatomicalDirectionalReferences.Blausen_0019_AnatomicalDirectionalReferences.png

Bipeds vs. quadrupeds

Human (bipedal)



Dog (quadrupedal)



https://upload.wikimedia.org/wikipedia/commons/thumb/0/00/1303_Human_Neuroaxis.jpg/800px-1303_Human_Neuroaxis.jpg

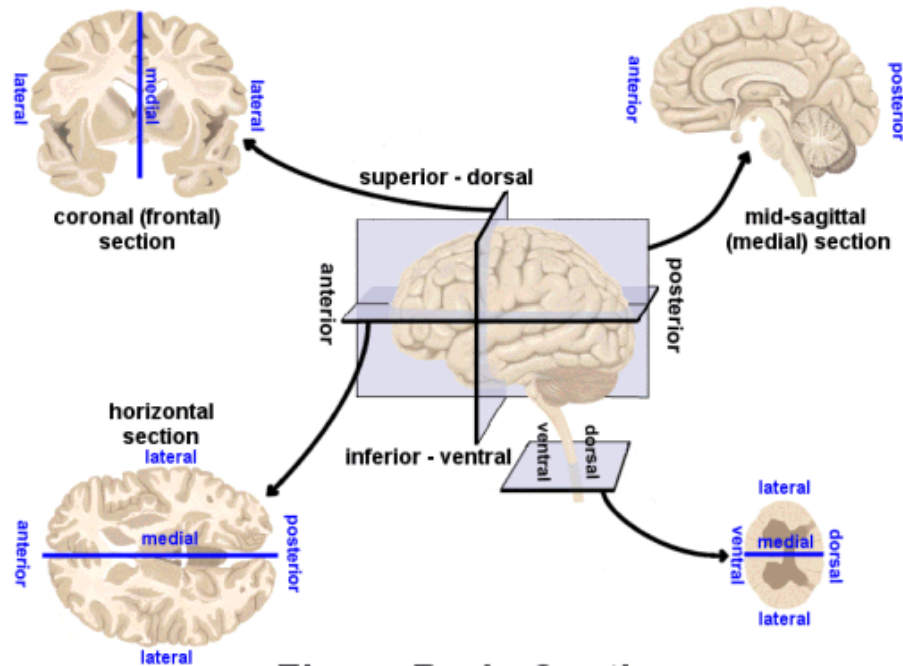
No matter how you slice it

Horizontal/Axial

Coronal/Transverse/Frontal

Sagittal (from the side)

Slice diagram



http://www.scienceteacherprogram.org/biology/chillemistudentguide1-06/brain_directions_planes_sections_directions_-_small.gif

Supporting structures

Meninges

Ventricular system

Blood supply

Meninges

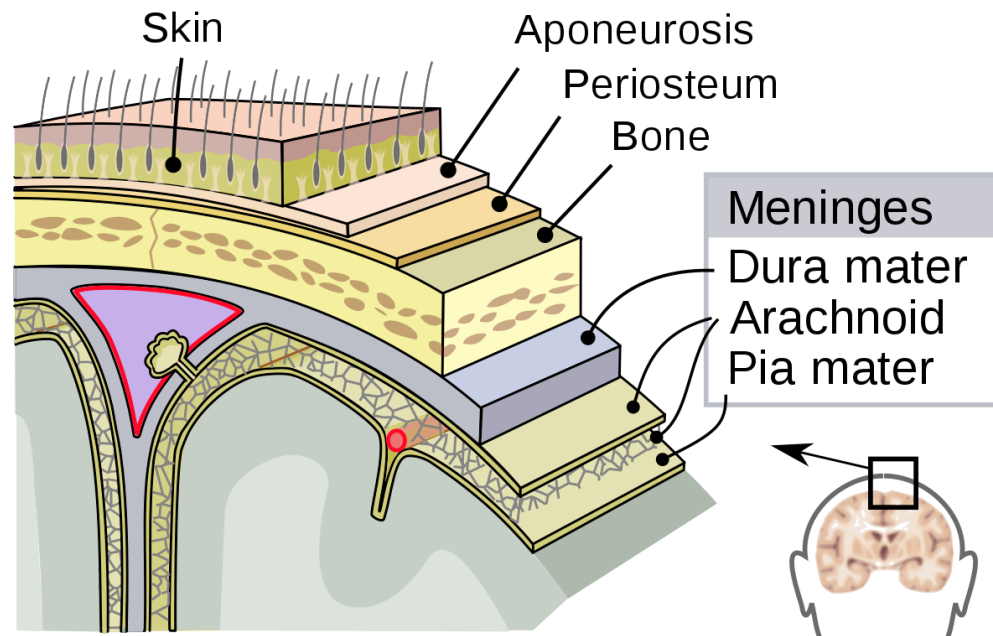
Dura mater ('tough mother')

Arachnoid membrane

Subarachnoid space

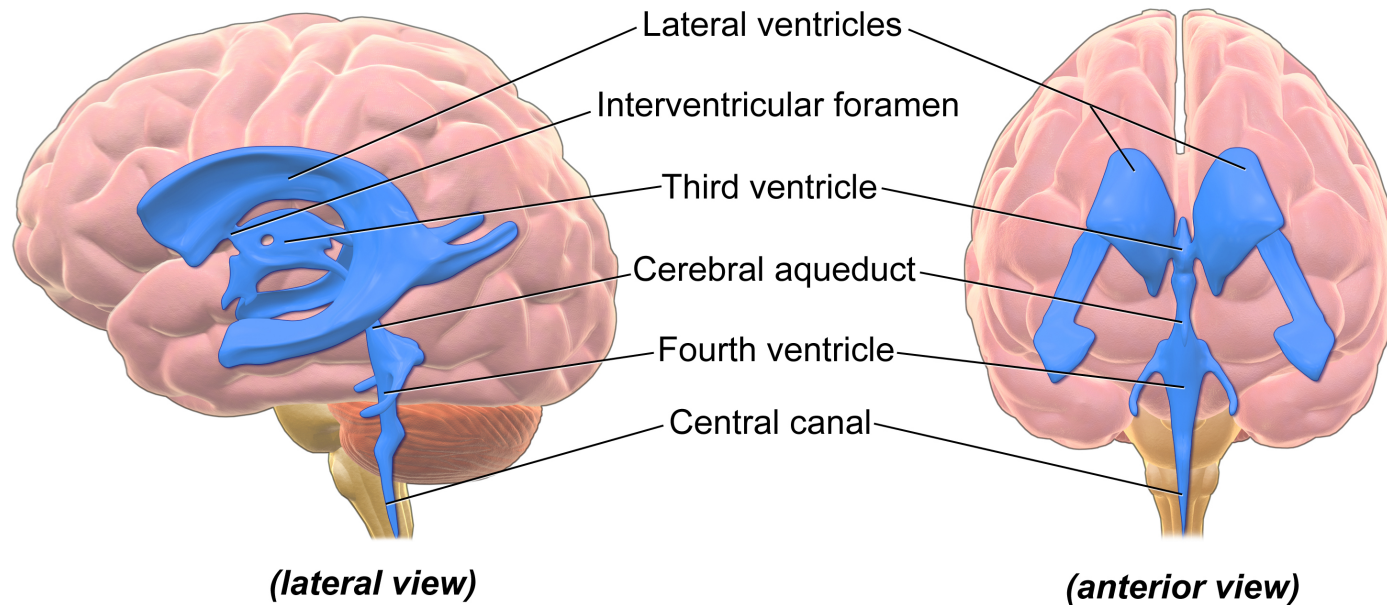
Pia mater ('gentle mother')

Meninges



<https://upload.wikimedia.org/wikipedia/commons/thumb/8/8e/Meninges-en.svg/1280px-Meninges-en.svg.png>

Ventricular system



https://upload.wikimedia.org/wikipedia/commons/d/d4/Blausen_0896_Ventricles_Brain.png

Ventricles

Lateral (1st & 2nd)

3rd

Cerebral aqueduct

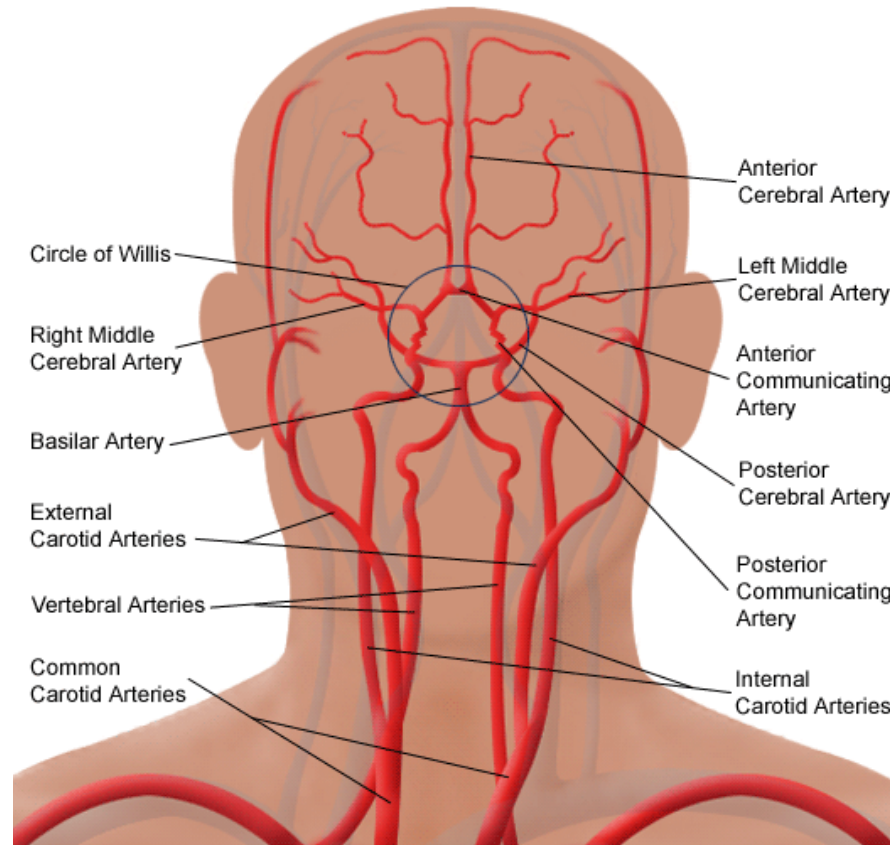
4th

Cerebrospinal fluid (CSF)

- Clears metabolites during sleep (Xie et al., 2013).

Blood Supply

Arterial Circulation of the Brain, Including Carotid Arteries



http://surgery.med.miami.edu/images/Circulation_of_brain.gif

Blood Supply

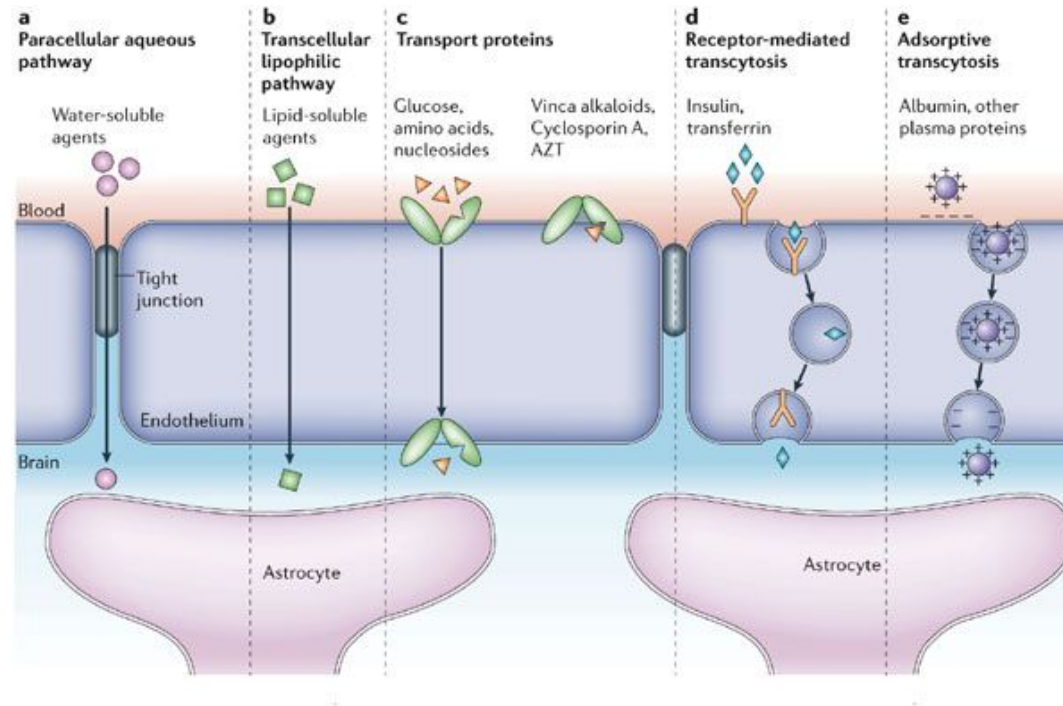
Arteries

- Circle of Willis

Blood/brain barrier

- Cells forming blood vessel walls tightly packed
- Active transport of molecules typically required

Blood/brain barrier

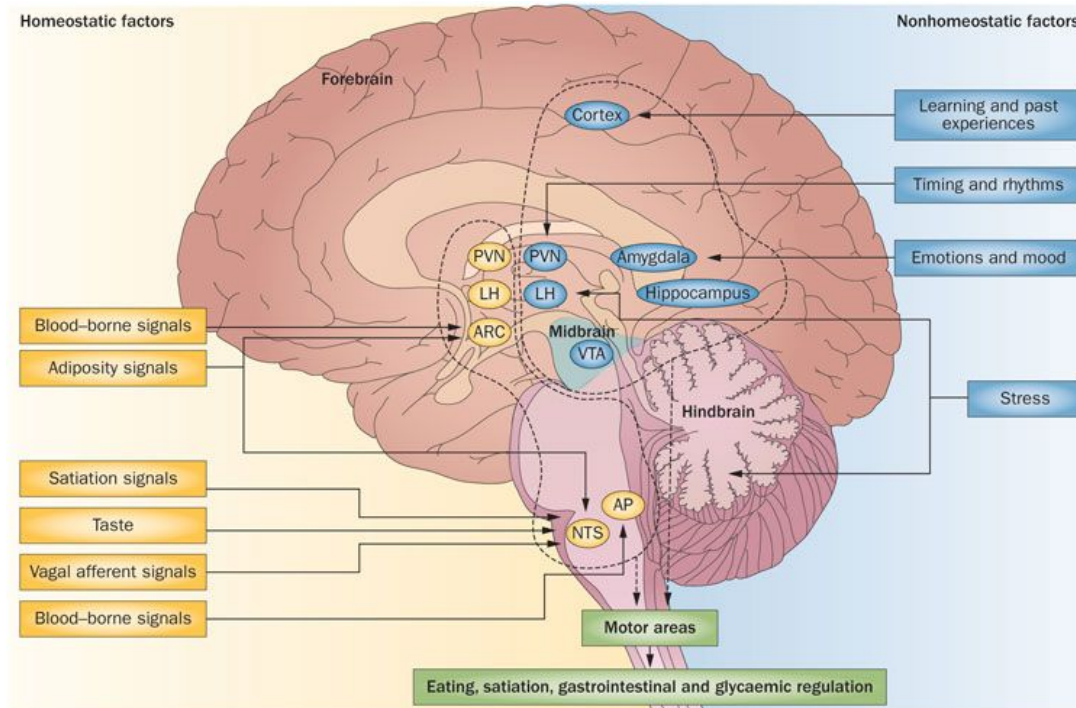


Copyright © 2005 Nature Publishing Group
Nature Reviews | Neuroscience

<http://www.nature.com/nrn/journal/v7/n1/images/nrn1824-f3.jpg>

Area Postrema

- Brainstem, blood-brain barrier thin



<http://www.nature.com/nrendo/journal/v9/n10/images/nrendo.2013.136-f2.jpg>

Organization of the Nervous System

Central Nervous System (CNS)

- Brain
- Spinal Cord
- Everything encased in bone

Peripheral Nervous System (PNS)

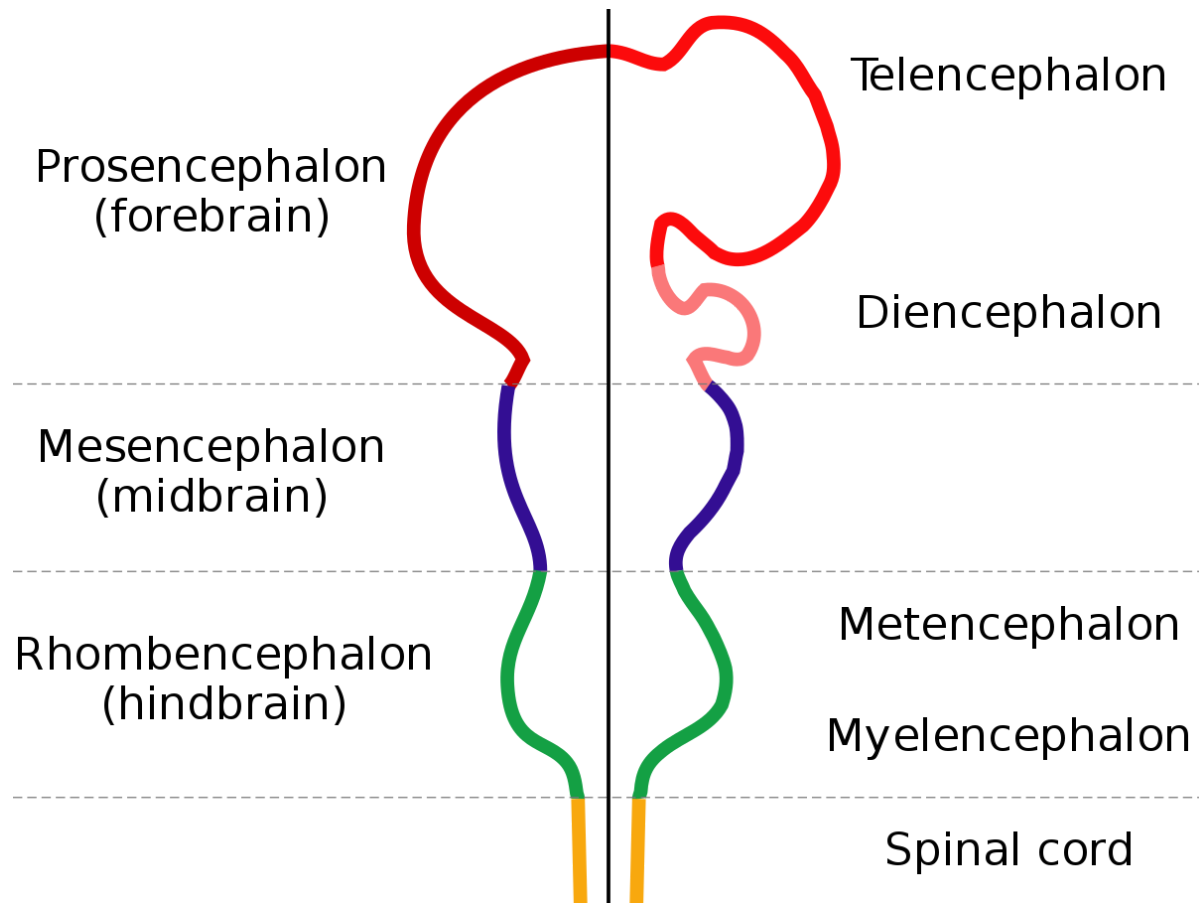
Organization of the brain

Major division	Ventricular Landmark	Embryonic Division	Structure
Forebrain	Lateral	Telencephalon	Cerebral cortex Basal ganglia Hippocampus, amygdala
	Third	Diencephalon	Thalamus Hypothalamus
Midbrain	Cerebral Aqueduct	Mesencephalon	Tectum, tegmentum

Organization of the brain

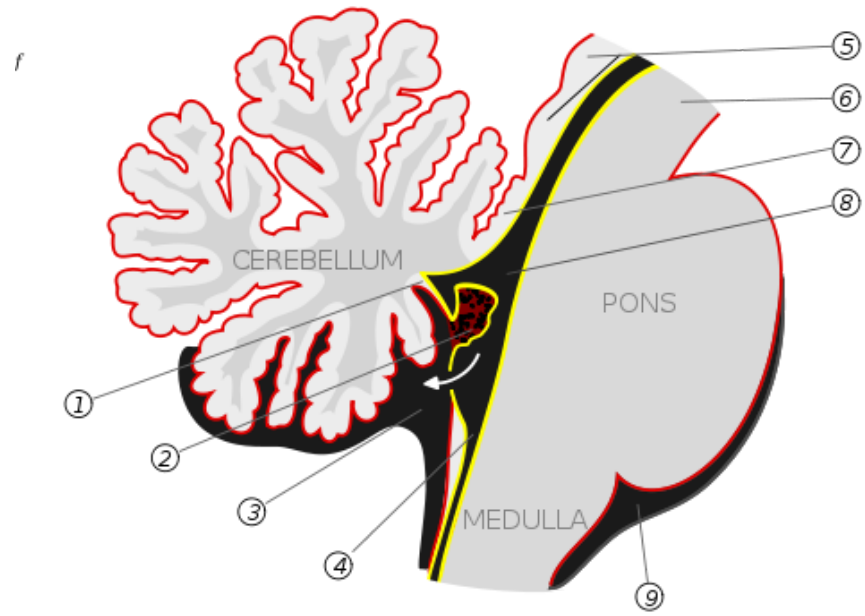
Major division	Ventricular Landmark	Embryonic Division	Structure
Hindbrain	4th	Metencephalon	Cerebellum, pons
	-	Myelencephalon	Medulla oblongata

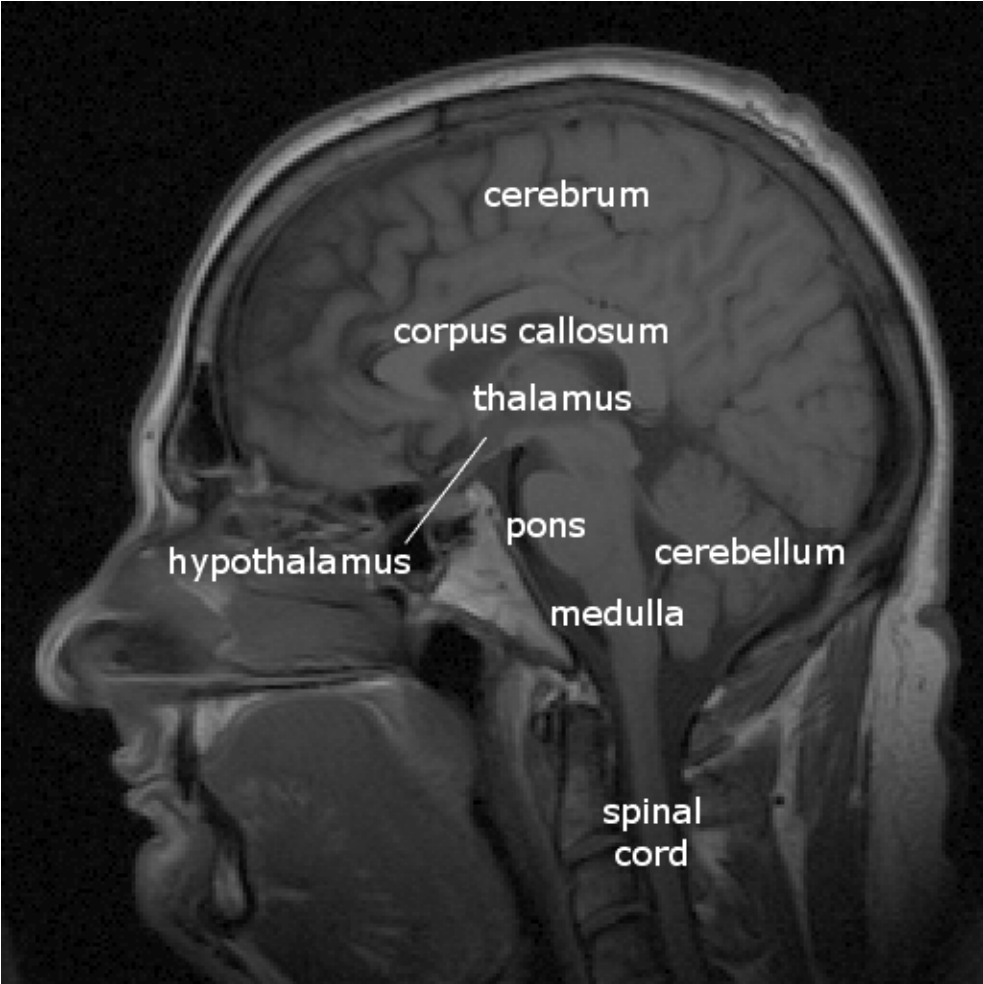
Hindbrain



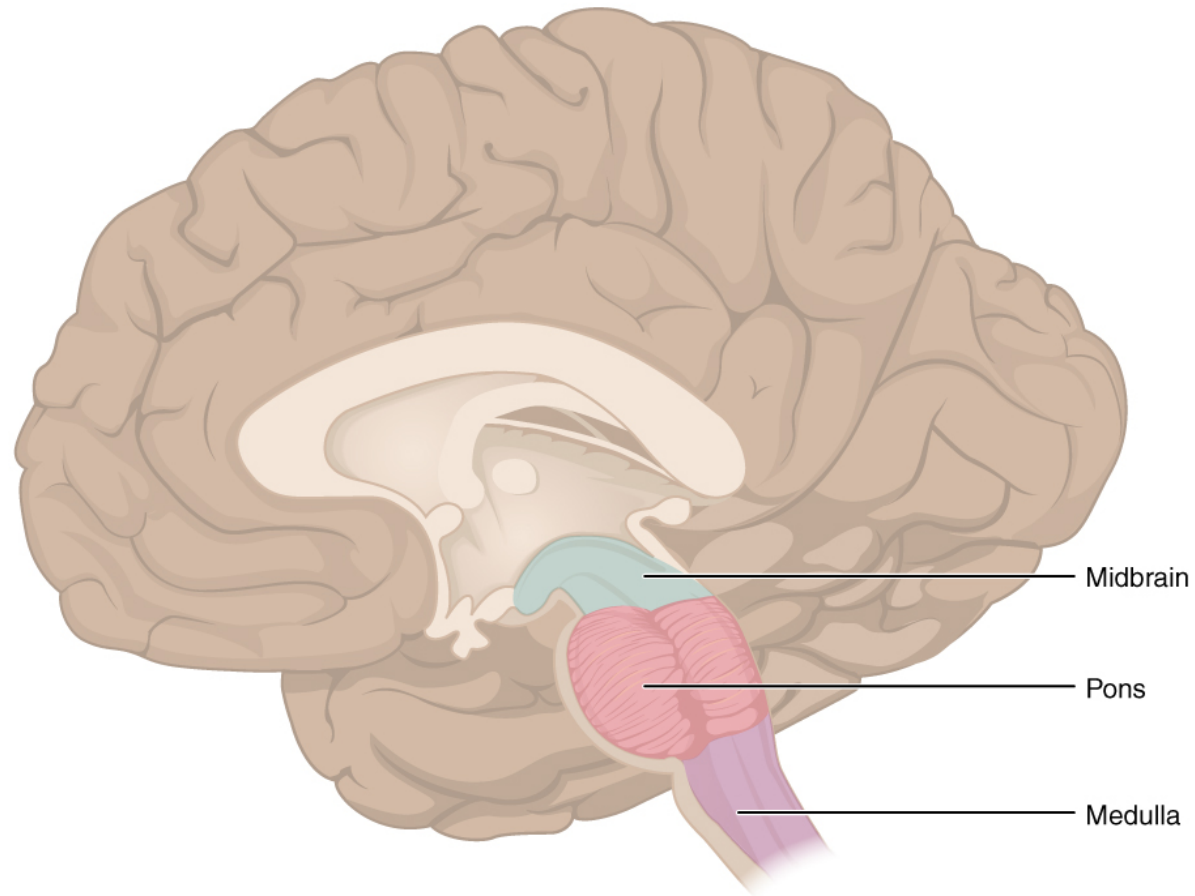
Hindbrain

- Structures adjacent to 4th ventricle
 - Medulla oblongata
 - Cerebellum
 - Pons





Medulla oblongata



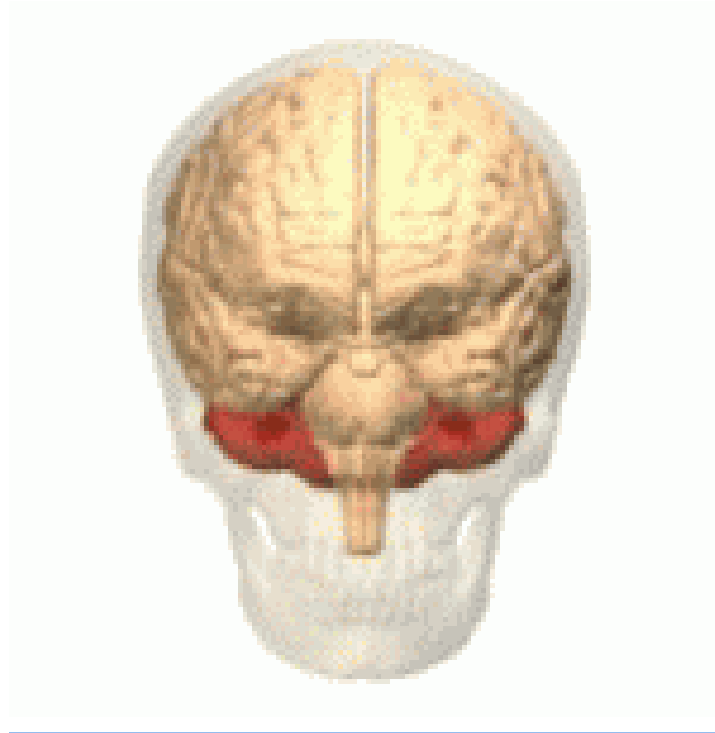
https://upload.wikimedia.org/wikipedia/commons/6/69/1311_Brain_Stem.jpg

Medulla

- Cardiovascular regulation
- Muscle tone
- Fibers of passage
 - Ascending fibers (from body), a.k.a. afferents
 - Descending fibers (exiting brain), a.k.a., efferents

Cerebellum

- “Little brain”
- Dorsal to pons
- Movement coordination, simple learning

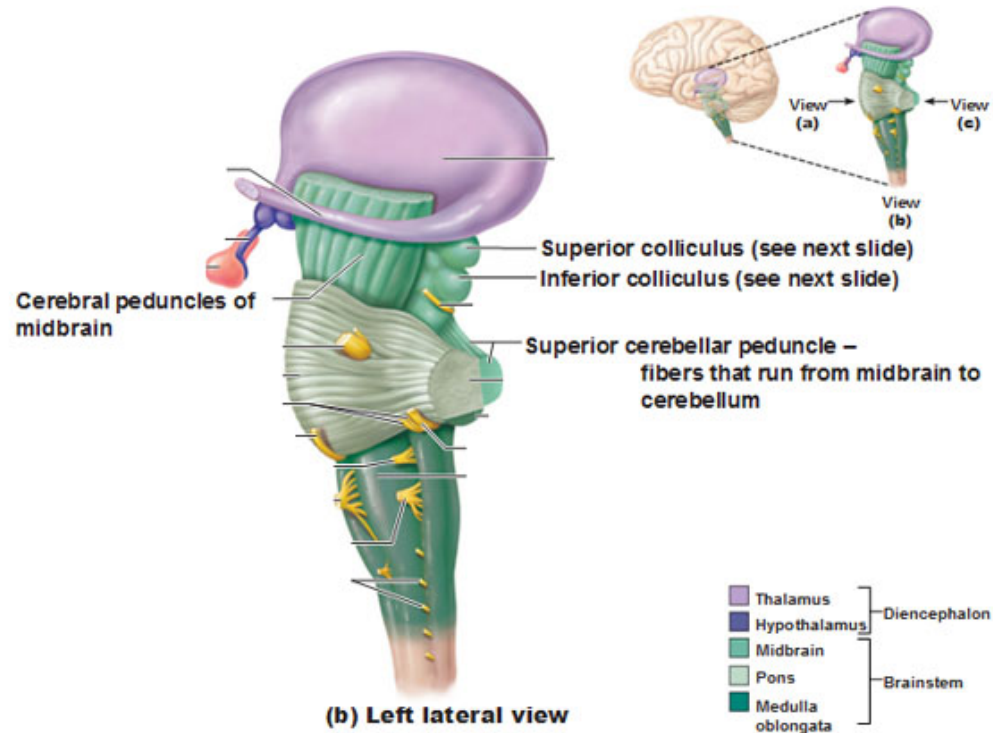


Pons

- Bulge on brain stem
- Neuromodulatory nuclei
- Relay to cerebellum

Midbrain

The Brain Stem– The Midbrain



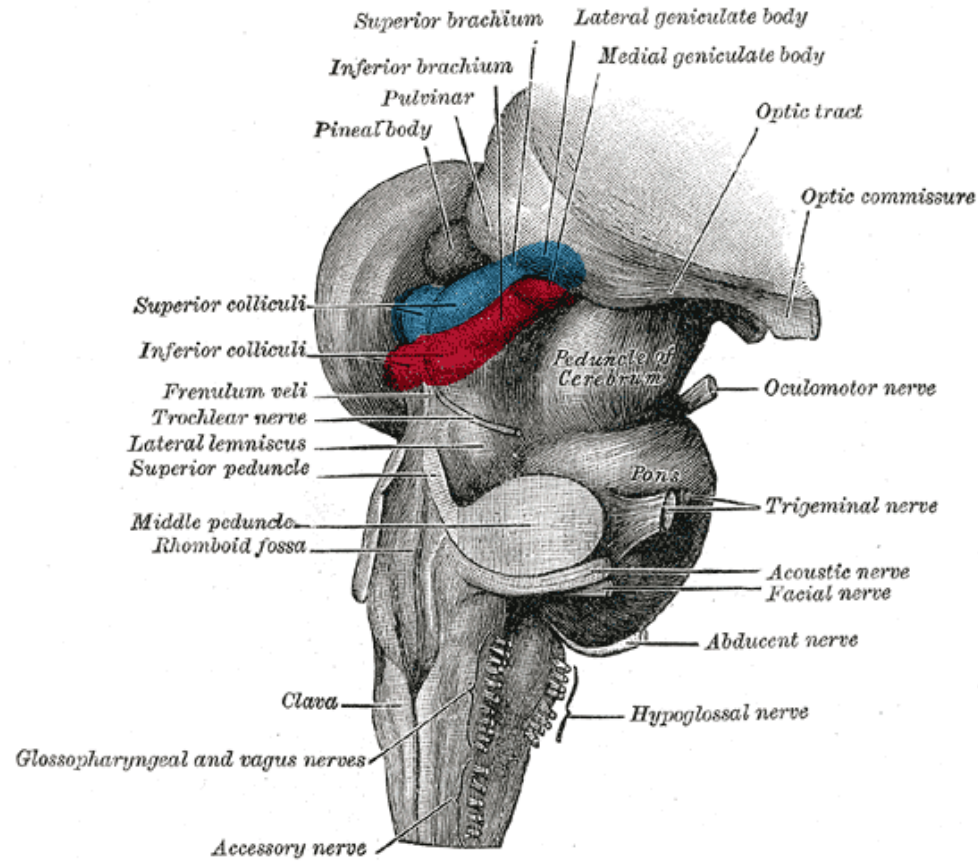
<http://antranik.org/wp-content/uploads/2011/11/the-brain-stem-mid-brain-left-lateral-view-superior-colliculus-inferior-cerebellar-peduncle.jpg>

Midbrain components

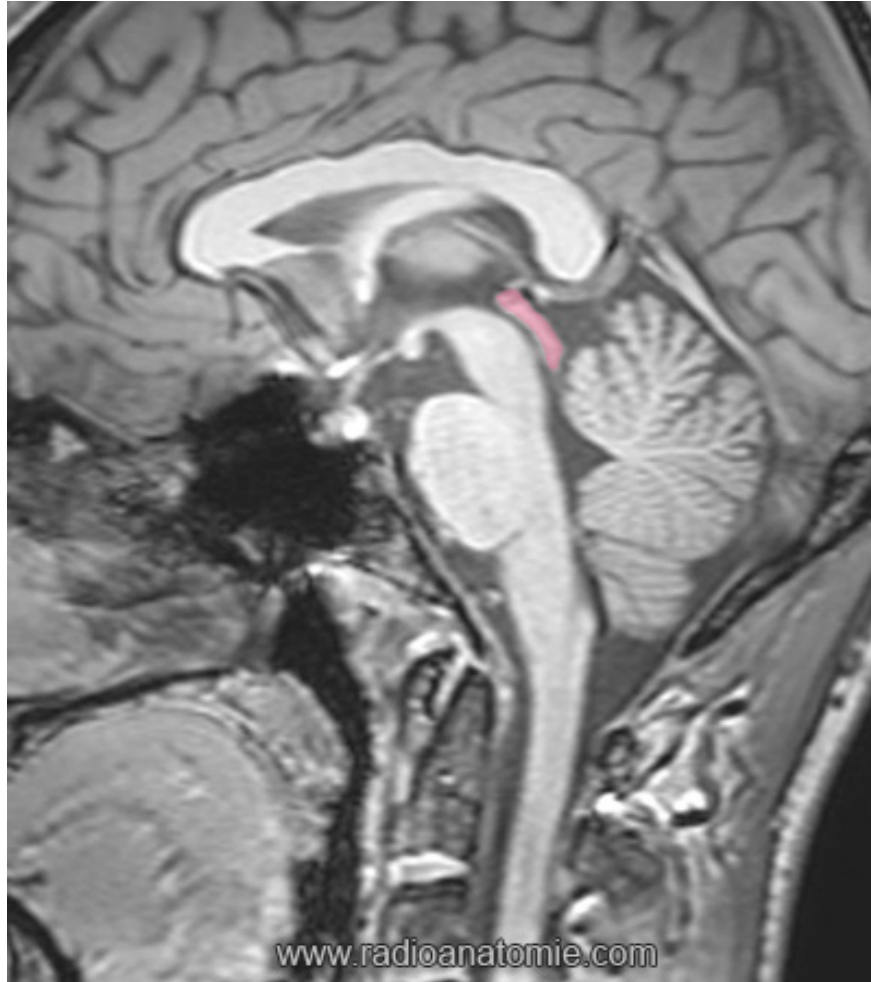
Tectum

Tegmentum

Tectum



<https://upload.wikimedia.org/wikipedia/commons/0/0b/Gray719.png>

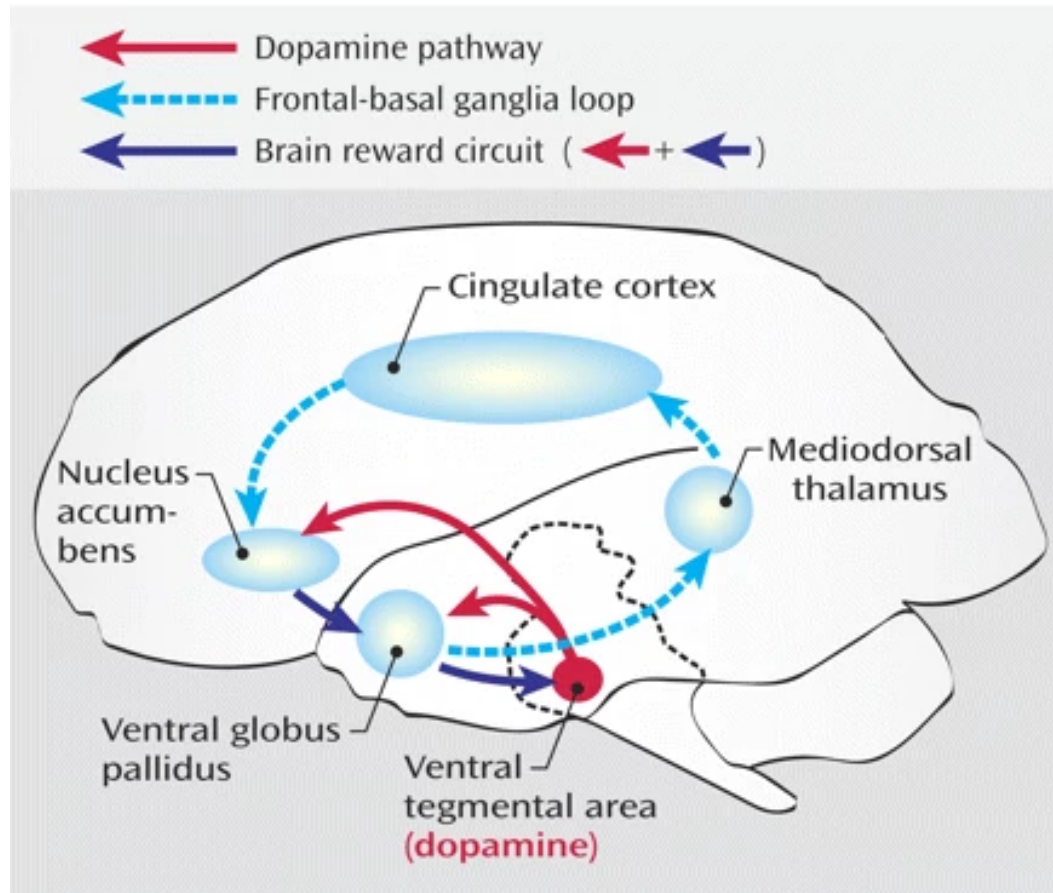


Tectum

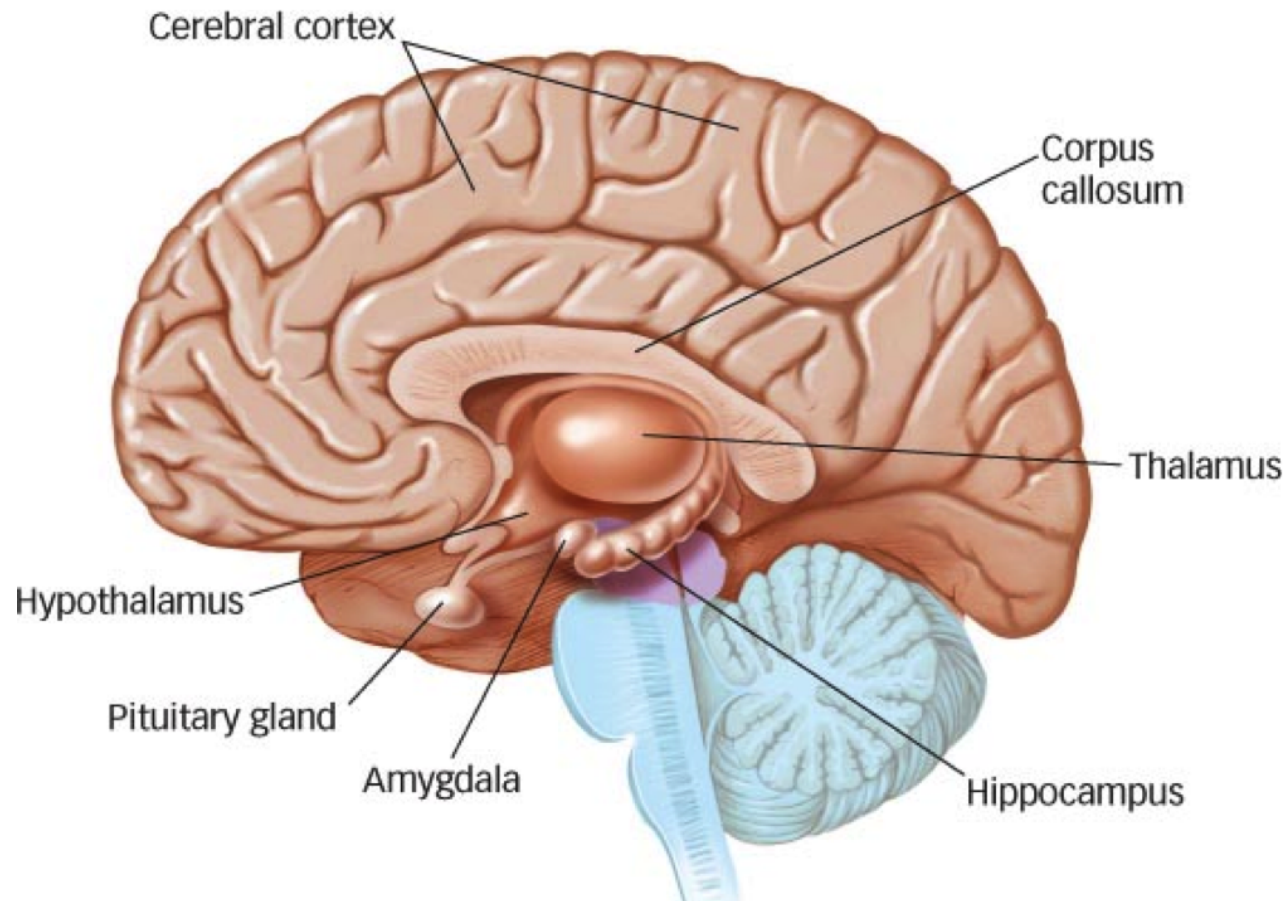
- "Roof" of the midbrain
- Superior and inferior colliculus
- Reflexive orienting of eyes, head, ears

Tegmentum

- "Floor" of the midbrain
- Species-typical movement sequences
- Neuromodulatory nuclei
 - Norepinephrine (NE)
 - Serotonin (5-HT)
 - Dopamine (DA) – from *ventral tegmental area (VTA)*



Forebrain



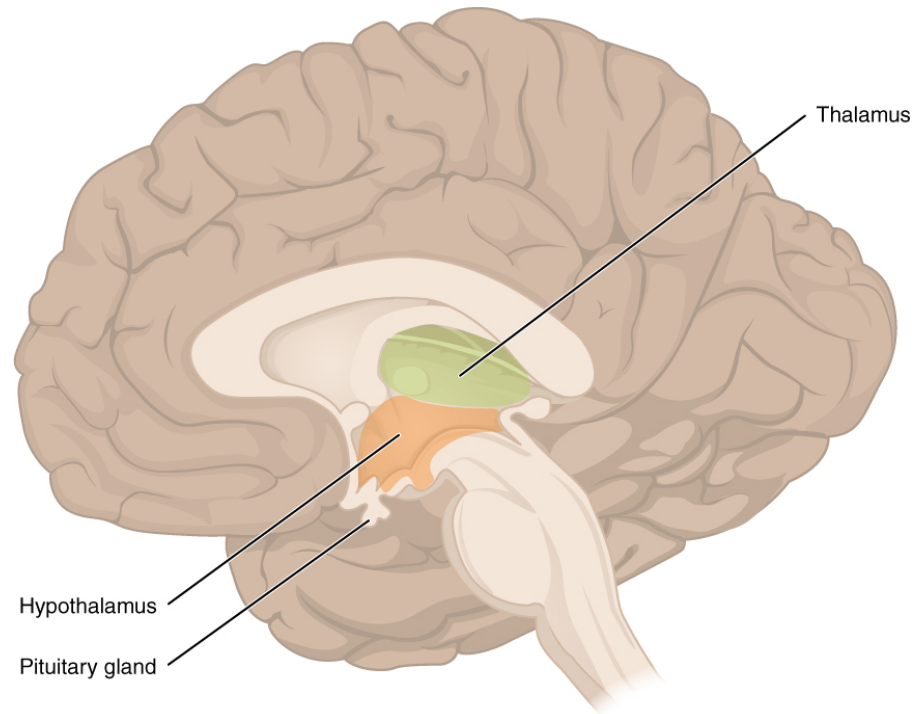
<http://classconnection.s3.amazonaws.com/252/flashcards/1048252/png/forebrain1328987872235.png>

Forebrain Components

Diencephalon

Telencephalon

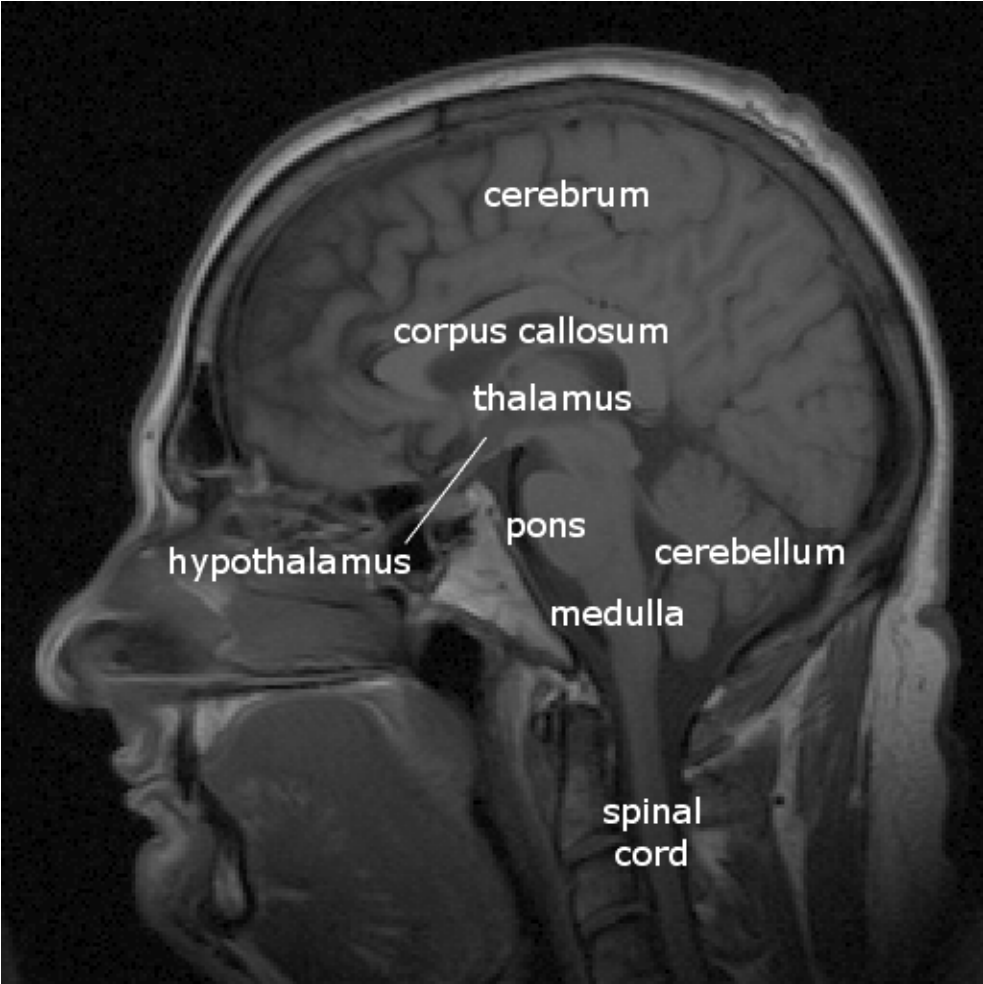
Diencephalon



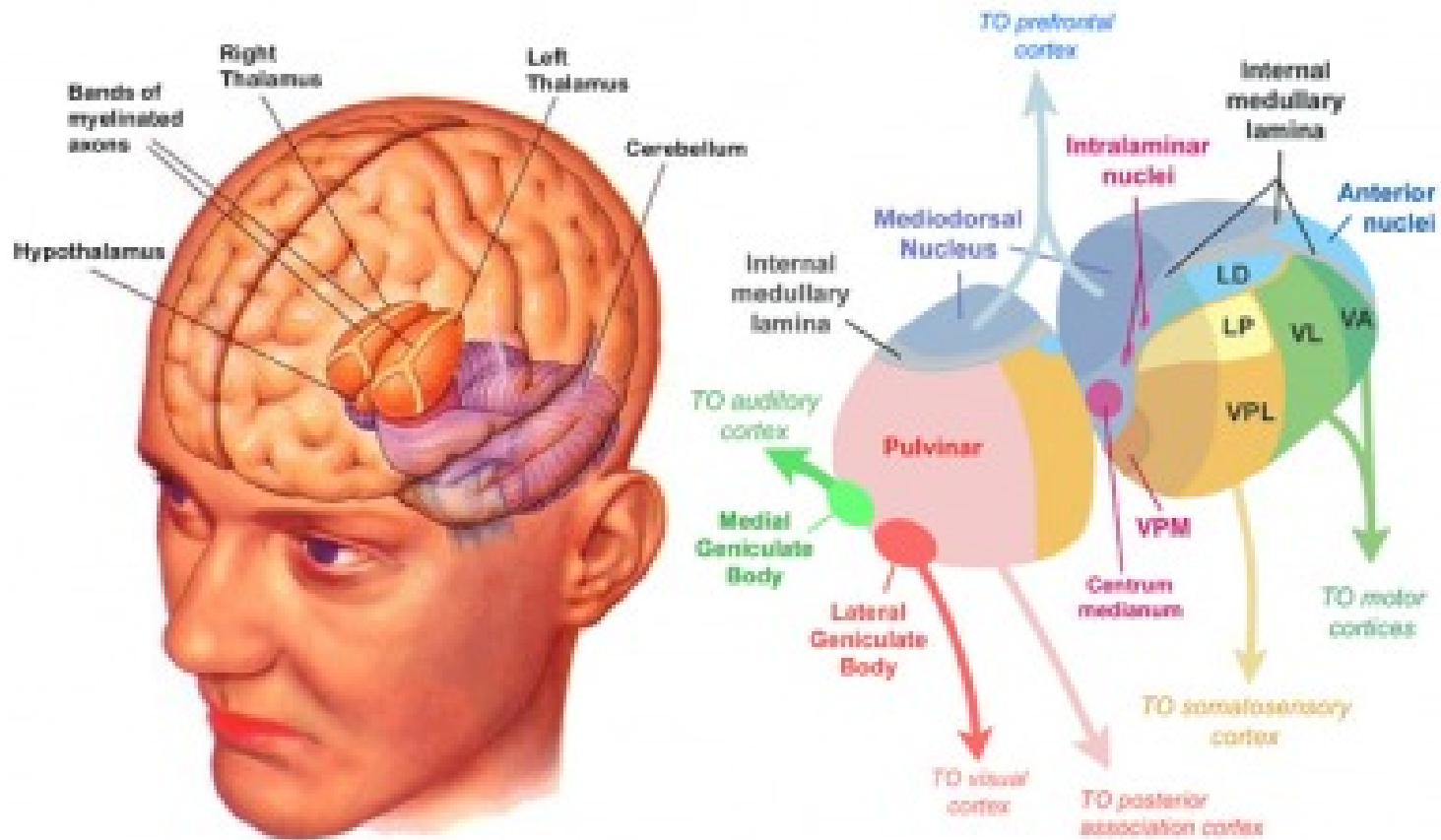
https://upload.wikimedia.org/wikipedia/commons/a/a0/1310_Diencephalon.jpg

Diencephalon Components

- Thalamus
- Hypothalamus



Thalamus



<http://neurobiologychapter3.weebly.com/uploads/1/4/1/8/1418733/5118342.jpg?401x231>

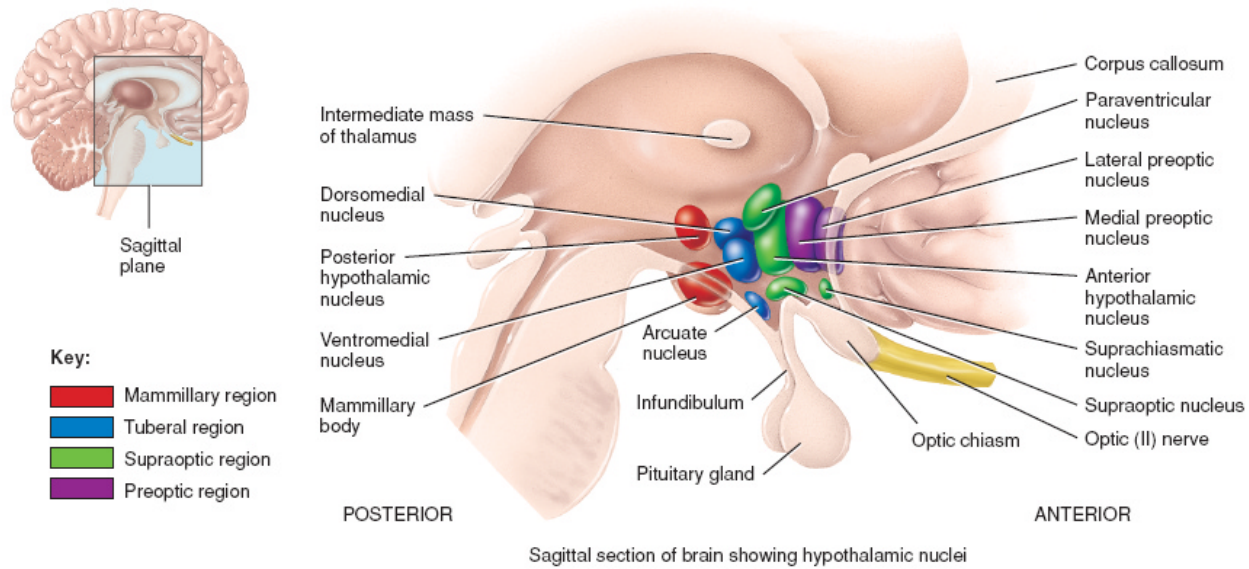
Thalamus functions

- Input to cortex
- Functionally distinct *nuclei* (collection of neurons)
 - Lateral geniculate nucleus (LGN), vision
 - Medial geniculate nucleus (MGN), audition
 - Pulvinar, attention?

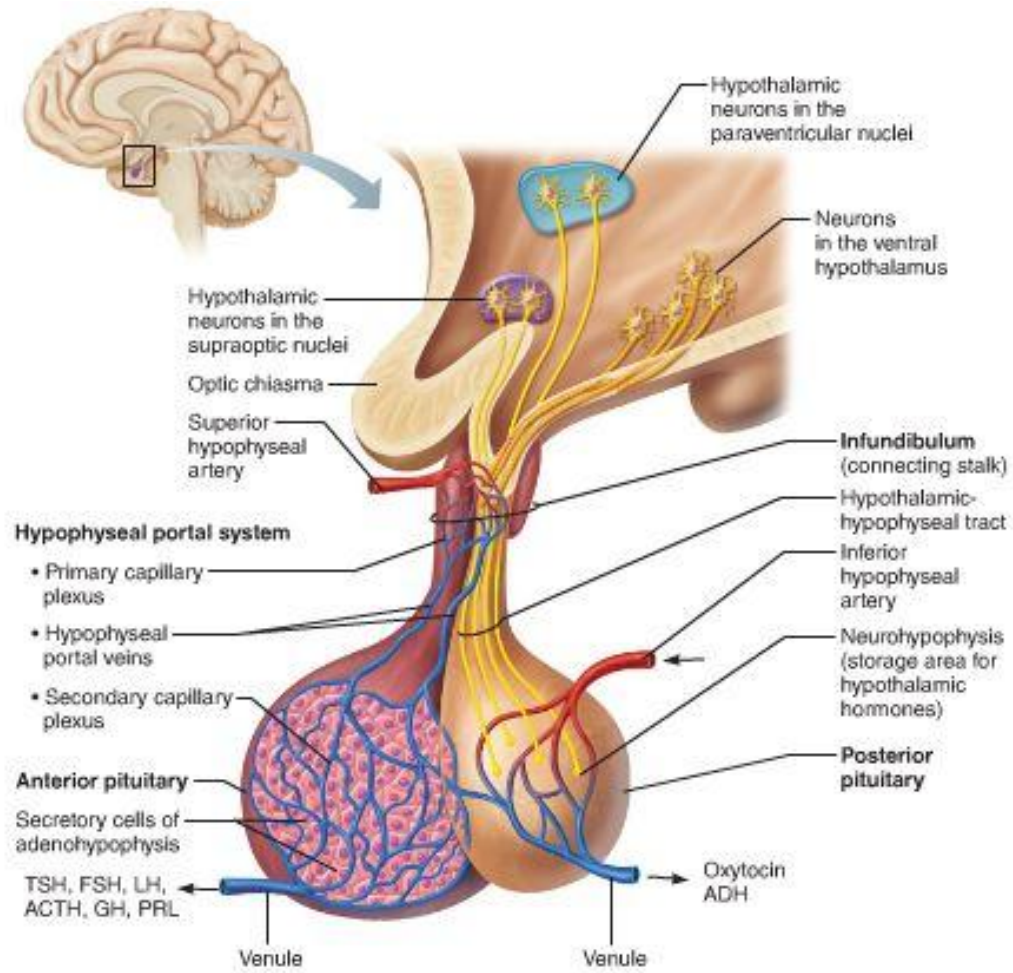
Hypothalamus

- Five Fs: fighting, fleeing/freezing, feeding, and reproduction
- Controls pituitary gland (“master” gland)
 - Anterior pituitary (indirect release of hormones)
 - e.g., Corticotropin Releasing Hormone (CRH) -> release of cortisol from Adrenal Cortex
 - Posterior pituitary (direct release of hormones)
 - Oxytocin
 - Vasopressin (aka, Arginine Vasopressin – AVP; Anti-diuretic Hormone – ADH)

Hypothalamus



http://higheredbcs.wiley.com/legacy/college/tortora/0470565101/hearthis_ill/pap13e_ch14_illustr_audio_mp3_ar



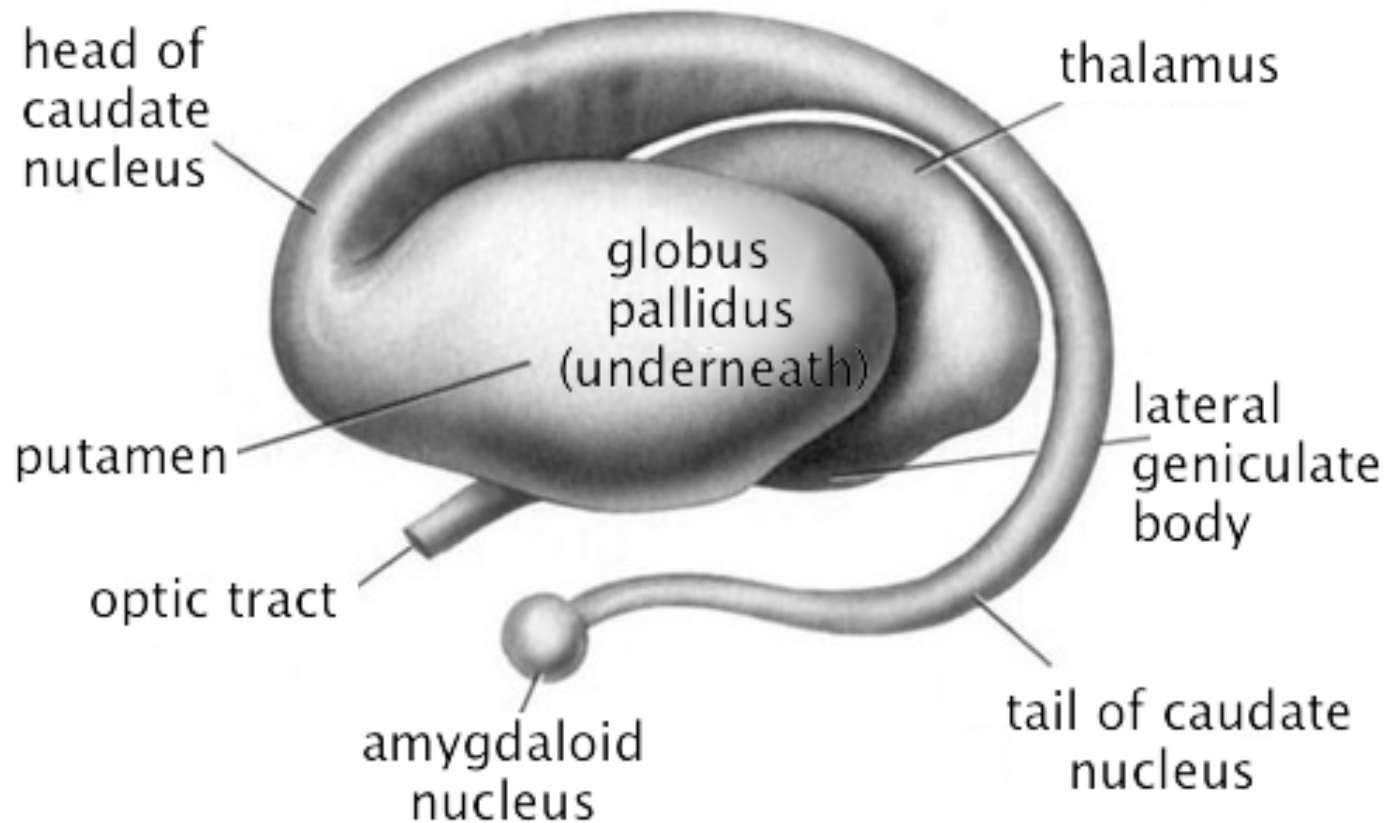
Telencephalon

- Basal ganglia
- Hippocampus, amygdala
- Cerebral cortex

Basal Ganglia

- Skill and habit learning
- Linked to Tourette syndrome, obsessive-compulsive disorder (OCD), addiction, movement disorders
- Example: Parkinson's Disease

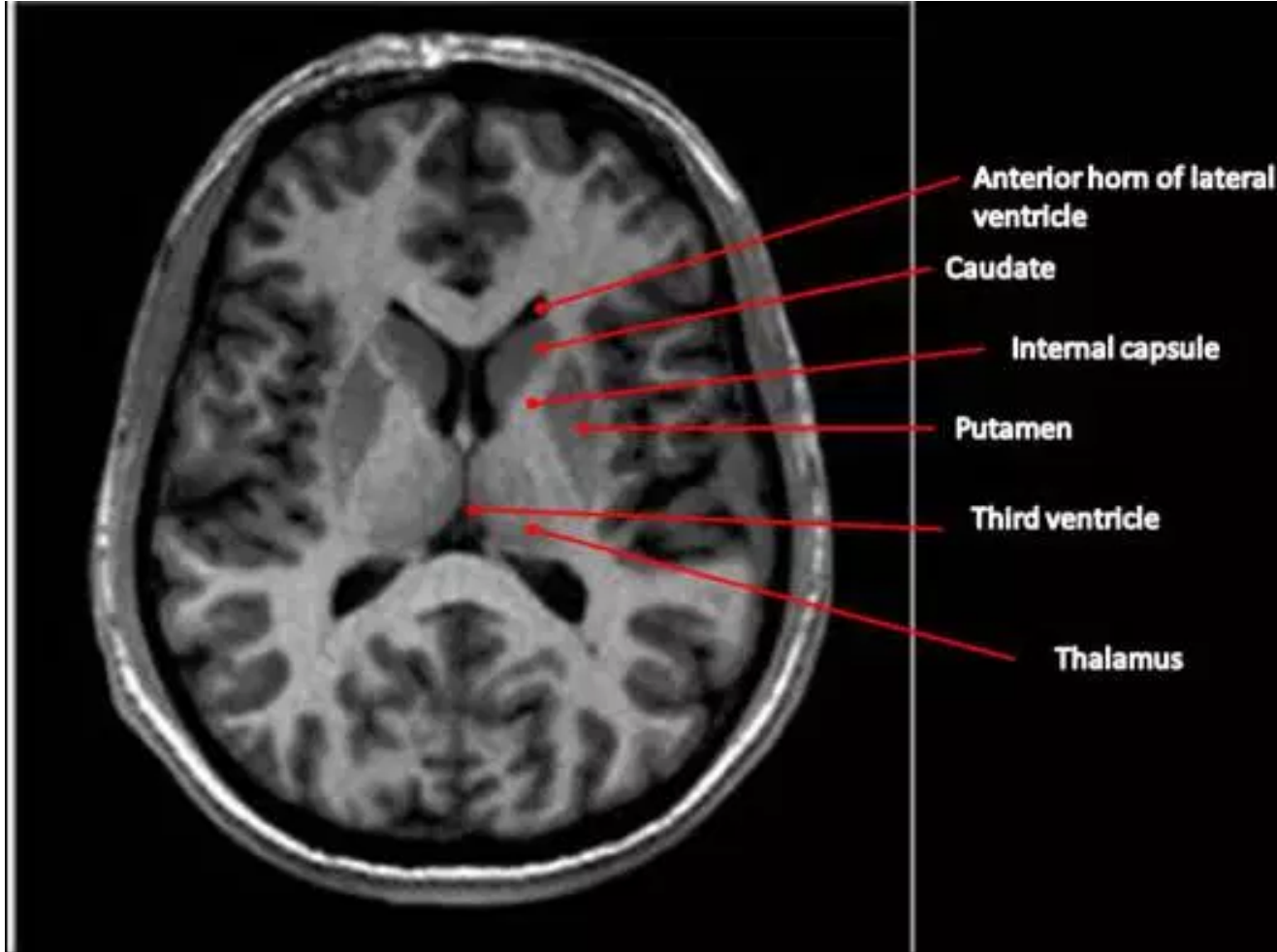
Basal ganglia



<http://webpace.ship.edu/cgboer/basalgangliagray.gif>

Basal ganglia

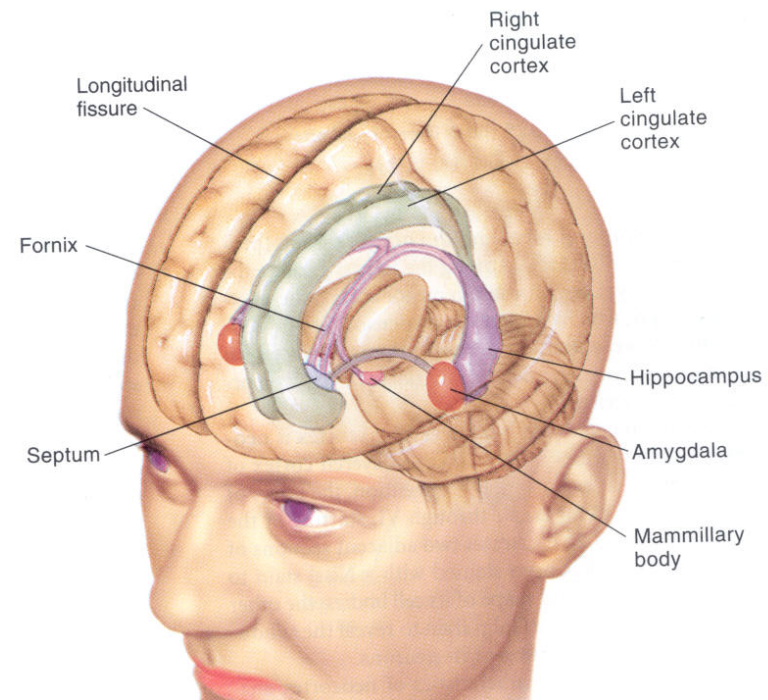
- Striatum
 - Caudate nucleus
 - Putamen
- Globus pallidus
- Subthalamic nucleus
- Substantia nigra (tegmentum)



Hippocampus

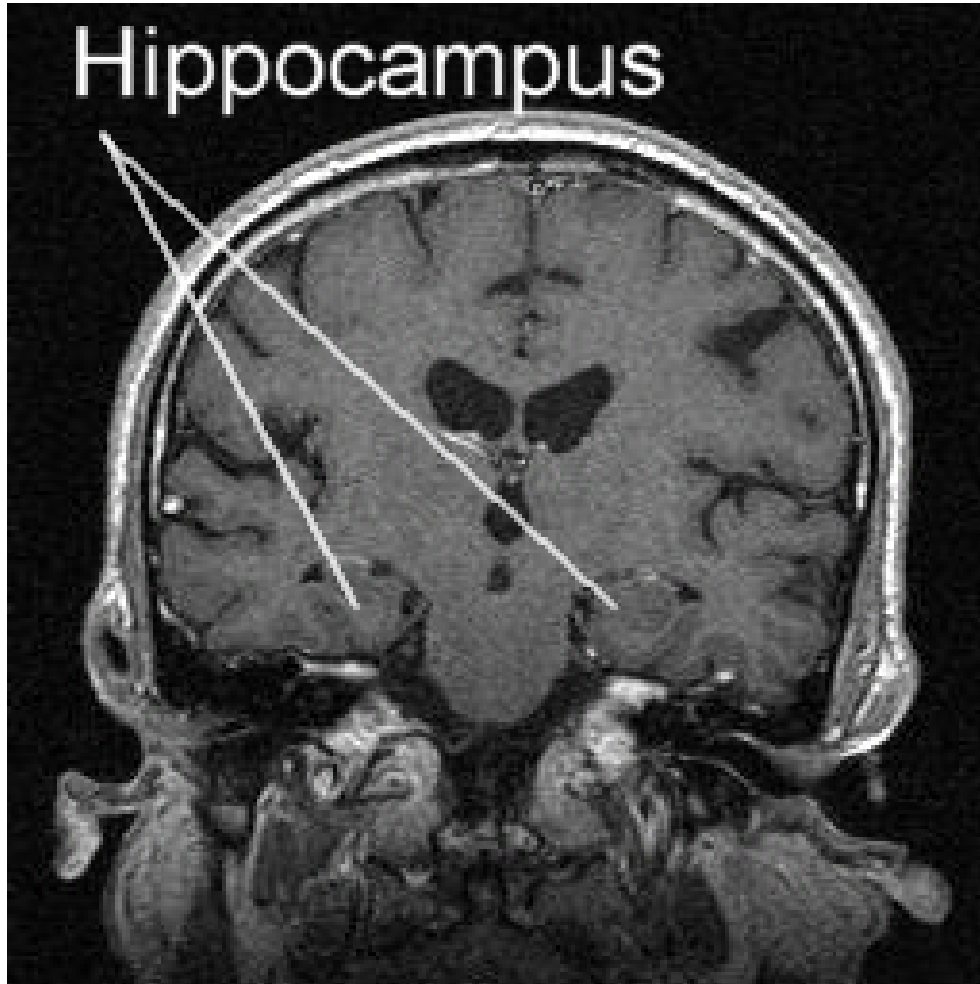
- Immediately lateral to lateral ventricles
- Memories of specific facts or events
- Fornix projects to hypothalamus
- Mammillary bodies

Hippocampus



http://homepage.smc.edu/wissmann_paul/physnet/anatomynet/anatomy/amy.jpg

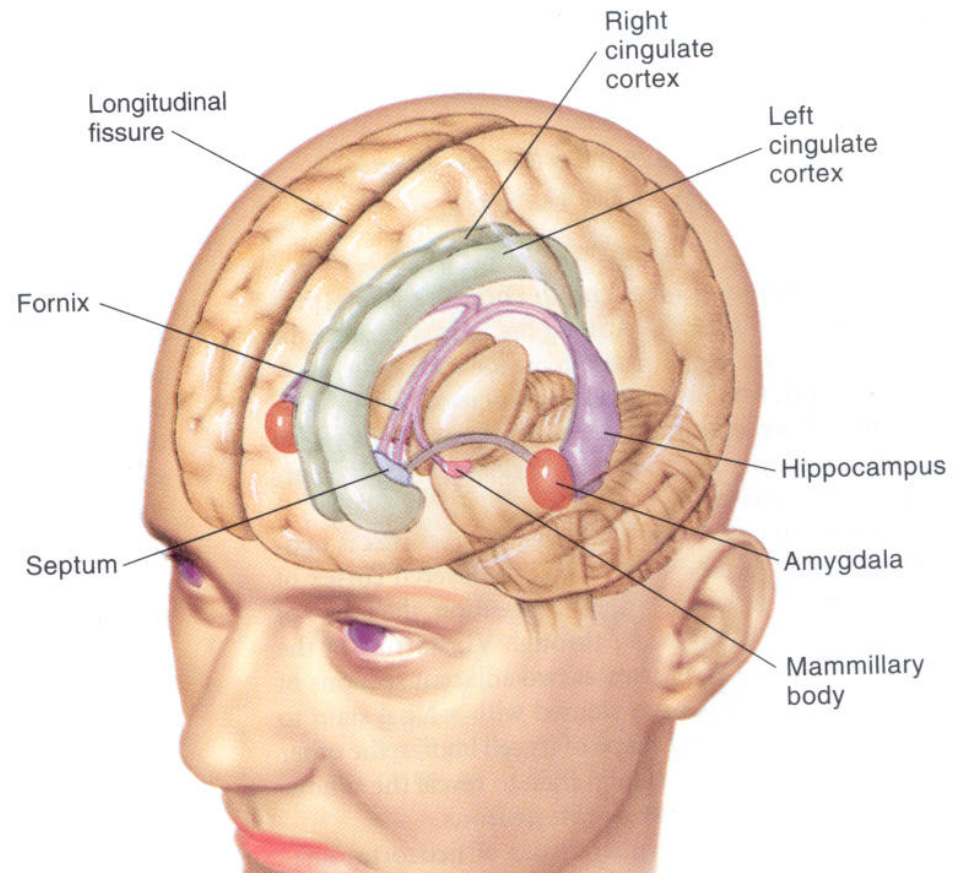
Hippocampus



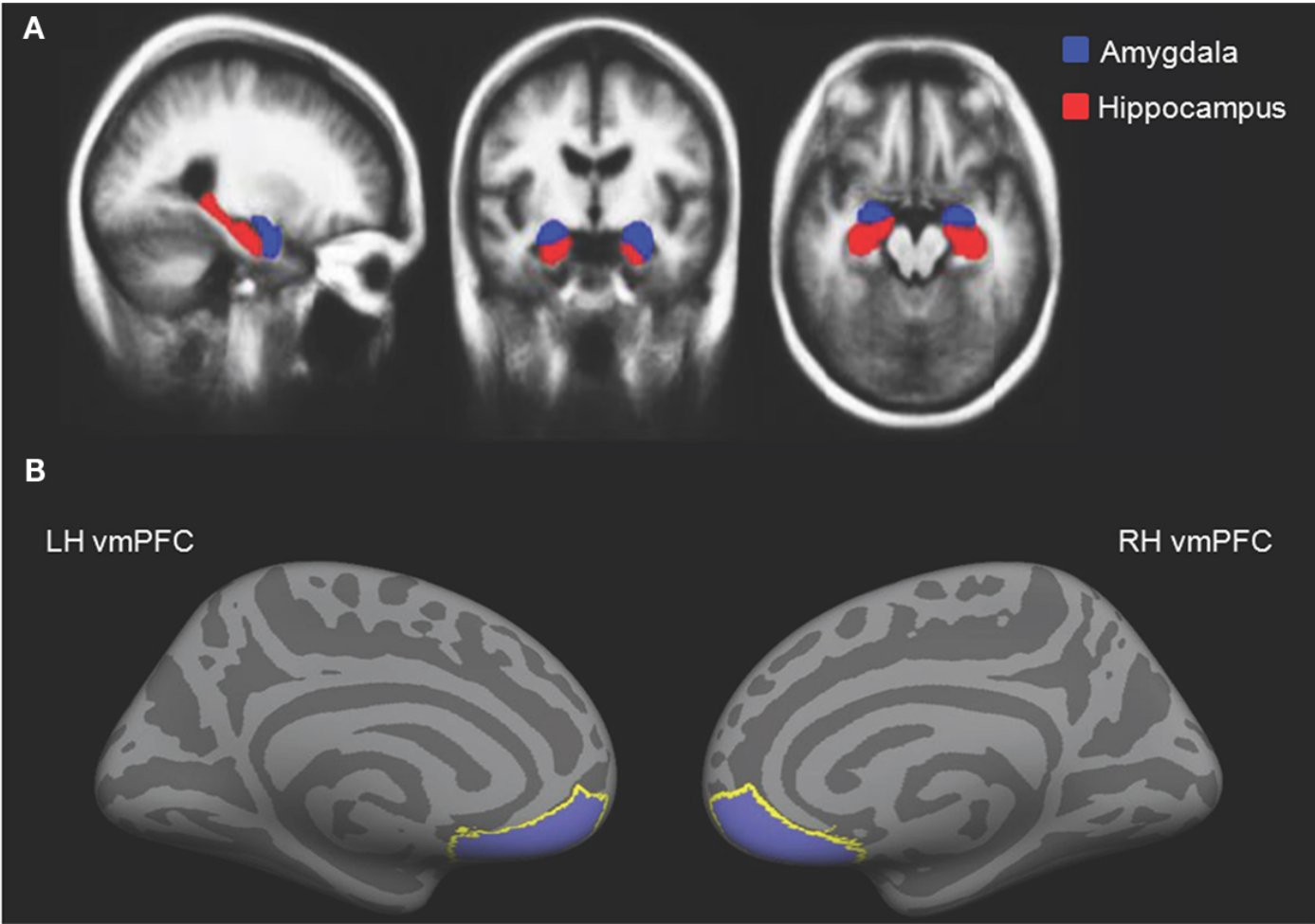
Amygdala (“almond”)

- Physiological state, behavioral readiness, affect
- NOT the fear center! (LeDoux, 2015).

Amygdala



http://homepage.smc.edu/wissmann_paul/physnet/anatomynet/anatomy/amy.jpg



Next time

- Gilmore's cautionary notes
- The cerebral cortex
- The peripheral nervous system

References

LeDoux, J. (2015, August 10). The Amygdala Is NOT the Brain's Fear Center. *Psychology Today*. Retrieved from <https://www.psychologytoday.com/blog/i-got-mind-tell-you/201508/the-amygdala-is-not-the-brains-fear-center>

Xie, L., Kang, H., Xu, Q., Chen, M. J., Liao, Y., Thiyagarajan, M., ... others. (2013). Sleep drives metabolite clearance from the adult brain. *Science*, 342(6156), 373–377. <https://doi.org/10.1126/science.1241224>